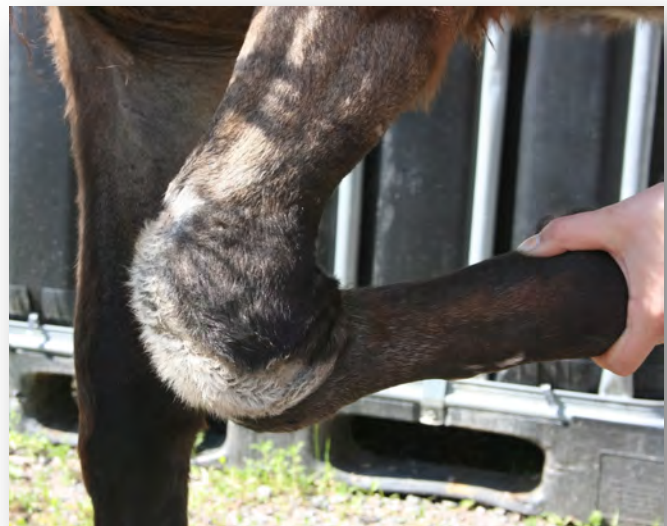
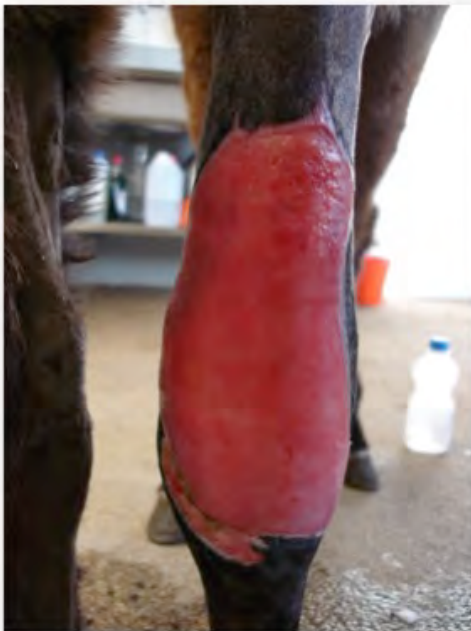
Why do we worry about granulation tissue when a wound is healing? Will that increase scar tissue or risk other and worse complications?"

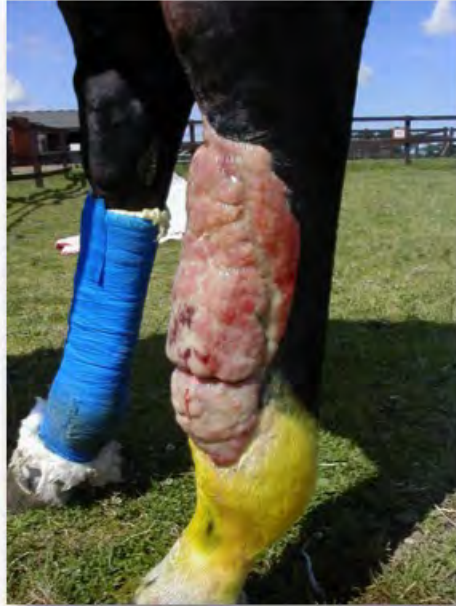This is a common question, however, in order to answer it I need to explain a little about what granulation tissue is and why the body makes it. In wounds that we are unable to suture closed, granulation tissue (granulationsvärvnad) is actually an essential part of the healing process. It has many functions:

- It fills in the wound gap
- It acts as a barrier to contamination
- It provides a lot of the really important cells the body needs to complete the repair
- It provides a 'bed' for the new skin cells to grow over

Healthy granulation tissue should be pink and smooth like in the picture below. This was an Icelandic foal that got its leg caught in a wire fence. Because it had lost so much skin, there was a large defect that had to fill in with new tissue. If we were to wait for the skin to grow in from the sides, this would take many months and the result would not be very good. In this case, we performed a skin transplant and after 6 weeks, the foal was pretty much back to normal.



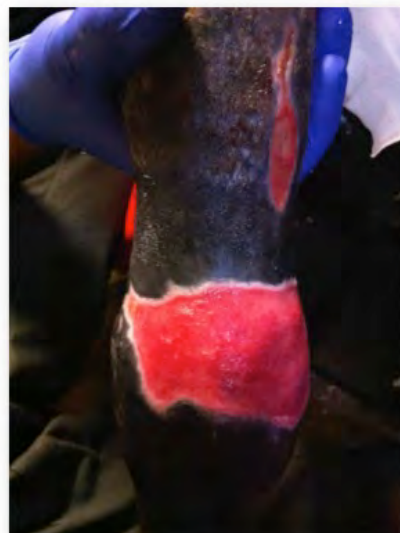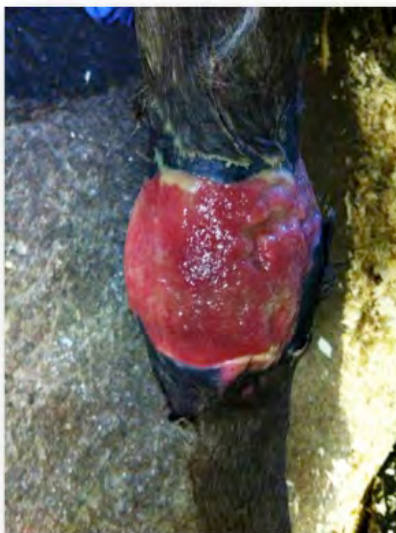Unfortunately, things don't always turn out his way. In the lower limb of the horse (below the knee and carpus), there is a higher chance that we will get exuberant granulation tissue (svallkött). This has a very different appearance as you can see below. It is really irregular and unhealthy looking, with lots of grooves and clefts. Unlike normal granulation tissue, it also protrudes over the wound edges.



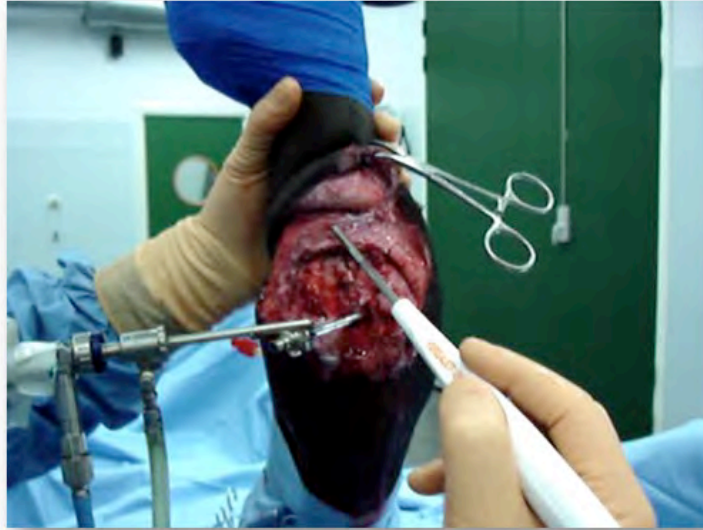
There are many reasons why this happens, but the most important ones are:

- The location of the wound (lower part of the leg)
- Too much movement
- Infection and inflammation
- Things that we do or put on the wound

When we get this sort of granulation tissue, the first thing that we need to do is to try and find out why it has happened. For example, if the wound is infected or has dead tissue, we need to deal with that first. There is always a reason! Normally this tissue needs to be removed. This should be done with a scalpel blade by your vet. If you apply caustic substances, such as Lotagen, it will kill all tissue and make the situation worse. With good wound management, unhealthy tissue can be converted to healthy tissue within 1 week, as you can see from the two pictures below.



So, you can see, granulation tissue can become a huge problem. That is why at Mälaren Hästklinik we put so much work into being aggressive at the start and try to close as many wounds as possible. To help us with this, we have a special instrument called a Versajet, that lets us get the wounds so clean, you could eat your dinner off it (if you should want to!).



If you need advice about a wound, please contact me at the clinic

Dylan Gorvy Dipl. ECVS
Klinikchef kirurgi

dylangorvy@hastklinik.se